

Anatomy in Practice:

Lumbar Zygapophysial Joint Palpation

Jon Cornwall, DipPhty, BSc(Physiol), DipMPhty, MSc(Anat),
Research Manipulative Physiotherapist,
Dunedin, New Zealand.

Susan R Mercer, PhD FNZCP,
Senior Lecturer,
Department of Anatomy and Structural Biology,
University of Otago, Dunedin, New Zealand.

ABSTRACT

It has been demonstrated that the zygapophysial joints can be the source of chronic low back pain. Some approaches to the assessment of the lumbar spine therefore advocate that palpation of the zygapophysial joints is useful in determining the side and level of their involvement. This commentary was undertaken to describe the clinical anatomy of the lumbar spine as it relates to palpation of the zygapophysial joints. It has highlighted the depth and location of the lumbar zygapophysial joints relative to other structures of the lumbar spine and in doing so raises questions regarding the purported specificity of the technique. Cornwall J, Mercer S (2004). **Anatomy in Practice: Lumbar Zygapophysial Joint Palpation.** *New Zealand Journal of Physiotherapy* 32(3) 140-142.

Keywords: lumbar zygapophysial joints, assessment, clinical anatomy.

INTRODUCTION

In manual therapy palpation of the lumbar spine is integral to the assessment of those patients who present with low back pain. Teaching within some approaches has promoted the concept that palpation may not only indicate the segmental level of dysfunction, but may also determine whether or not the zygapophysial joints are causing pain and, if so, identify the side and level of involvement (Burns & Mierau 1997; Giles & Singer 1997). In particular, pain and stiffness have been nominated as symptoms that should be noted as comparative signs for treatment and re-evaluation (Grieve 1991; Maitland 1986). In addition to joint movement changes, palpation is used to detect associated tissue changes (i.e. texture and consistency of the muscular and connective tissues) that can indicate which interventions may be useful when deciding on a treatment regime (Grieve 1991; McClune et al. 1997).

When palpating over the articular pillar, pressure is applied by the thumb or medial border of the hand distal to the pisiform. It has also been suggested that for increased comfort during a unilateral posteroanterior (P/A) pressure the paravertebral musculature should be pushed laterally so that the bulk of this muscle is not squashed against the underlying articular pillar (Edmondston & Elvey 1997).

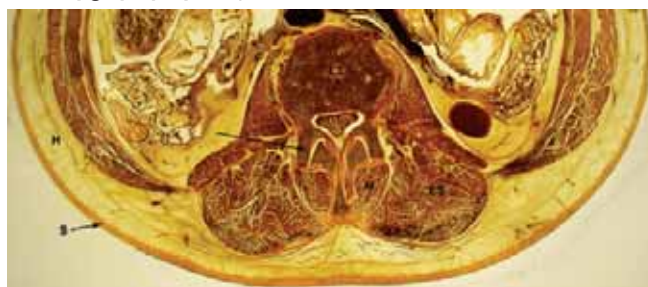
Traditionally anatomical education during the undergraduate years has focused on the acquisition of the language of anatomy and on basic knowledge of the structure and function of the human body. But clinical anatomy, with its emphasis on using anatomical findings as a service to the clinical

community provides us with the opportunity to consider the biological basis of many treatment and assessment techniques including palpation (Mercer & Rivett 2004). Therefore, the purpose of this clinical commentary was to report on anatomical aspects of palpation that need to be considered when assessing the lumbar zygapophysial joints.

Clinical Anatomy

Assessment of the zygapophysial joints is not straightforward. When palpating the lumbar spine unilaterally the therapist must consider a number of potential pain generating structures that lie between the skin and the zygapophysial joints. From superficial to deep these include the skin, subcutaneous tissue, the thoracolumbar fascia, the erector spinae aponeurosis, and the multifidus muscle (Bogduk 1997) (Figures 1 and 2). As all of these structures have a similar segmental level of innervation they all have the potential to elicit similar patterns of low back, thigh and leg pain (Kellgren 1938; Howarth et al. 1994; Yahia et al. 1992; Coppes et al. 1997).

Figure 1. Top views of transverse sections through (a) the L2/3 zygapophysial joints and



(b) the L4/5 zygapophysial joints. Black arrow = zygapophysial joint, S = skin, H = subcutaneous tissue, M = multifidus, ES = erector spinae, L3 = L3 vertebral body, L4/5 = L4/5 intervertebral disc

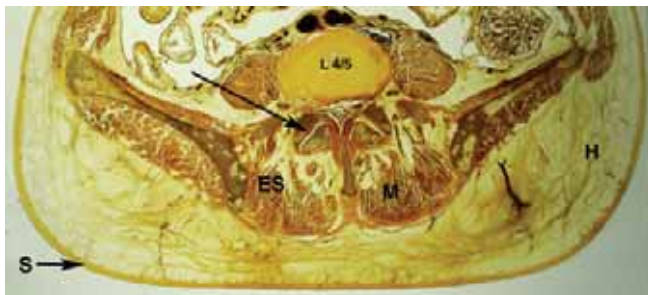
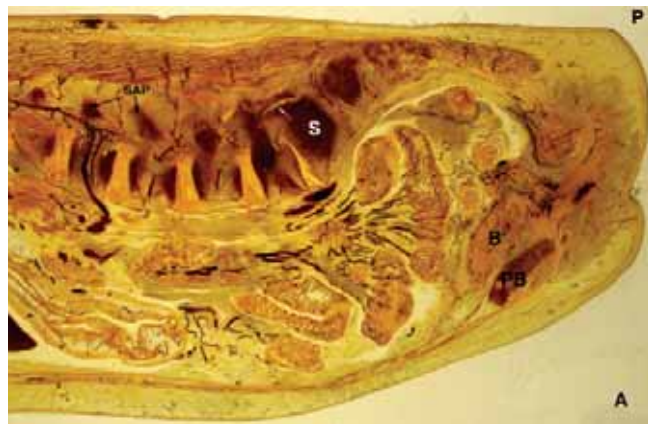

Figure 2. Sagittal section through the lumbar spine. Note the depth and relationships of the L5/S1 zygapophysial joint and upper lumbar superior articular processes. S = sacrum, white arrow = L5/S1 zygapophysial joint, SAP = superior articular processes, PB = pubic bone, B = bladder, A = anterior, P = posterior.



Immediately below the skin, the body's largest sensory organ, lies the subcutaneous tissue that varies widely in thickness from patient to patient. Deeper, the tough posterior layer of the thoracolumbar fascia is found, followed by the substantial aponeurosis of the erector spinae muscles. The posterior layer of the thoracolumbar fascia is formed by the aponeurosis of the latissimus dorsi muscle. It consists of two laminae – a superficial lamina derived from the ipsilateral latissimus dorsi and a deep lamina from the contralateral muscle (Bogduk and Macintosh 1984). Free nerve endings and encapsulated mechanoreceptors (Ruffini's and Vater-Pacini corpuscles) have been identified in this tissue leading to suggestions that the thoracolumbar fascia may play a neurosensory role (Yahia et al. 1992). Directly below the thoracolumbar fascia lie the tendons of the thoracic erector spinae muscles forming a broad thick aponeurosis that spans the lumbar region to gain attachment to the ilium, sacrum and lumbar and sacral spinous processes (Macintosh and Bogduk 1986) (Figures 1 and 2).

The multifidus muscle, the largest of the lumbar back muscles, passes directly over the

zygapophysial joints between them and the overlying erector spinae aponeurosis. The larger fascicles of the multifidus muscle originate from the spinous process of the vertebrae at least three segments above their level of insertion, and run inferiorly, laterally and anteriorly to insert into the mamillary process and zygapophysial joint capsule (Lewin et al. 1962; Macintosh et al. 1986). In the lower part of the lumbar spine the pattern is modified, as the fascicles insert into the sacrum and iliac crest, giving the impression that multifidus fans out in a tree-like fashion as it approaches the sacrum (Figure 3). The laminar fibres of multifidus, run between the lamina of the vertebrae, and the mamillary process of the vertebra two levels caudad (Bogduk 1997). Therefore, higher in the lumbar spine the multifidus will lie closer to the midline and so palpation believed by the therapist to be over the zygapophysial joints may also occur through the longissimus portion of the erector spinae muscles (Figure 1a) while lower the multifidus will more completely cover the zygapophysial joint (Figure 1b).

In addition to considering the nature of the overlying tissues, therapists must take into account the depth of the zygapophysial joints, where the posterior aspect (for example) of the L4/5 joint may lie between 3 and 6 cm below the skin (Grieve 1991) (Figures 1 and 2). Measurements taken from magnetic resonance images of a male (52yrs) and a female (47 yrs) at the L5/S1 zygapophysial joints showed a distance of 5.7 – 6.5 cms from the posterior aspect of the joint to the nearest point of the skin. These findings agreed with a series of informal measurements taken on available adult human male and female embalmed cadavers where the depth of the lumbar zygapophysial joints ranged from 4 to 8 cms. Access to the L5-S1 zygapophysial joint is further limited as the joint is located below the level of the iliac crest (Figure 4).

Figure 3. Posterior view of the thoracolumbar spine. The lumbar multifidus muscle fans out as inferiorly it approaches the sacrum. ESA = erector spinae aponeurosis, TLF = thoracolumbar fascia, M = multifidus, lc = ilicostalis lumborum pars lumborum, L = longissimus thoracis pars lumborum.

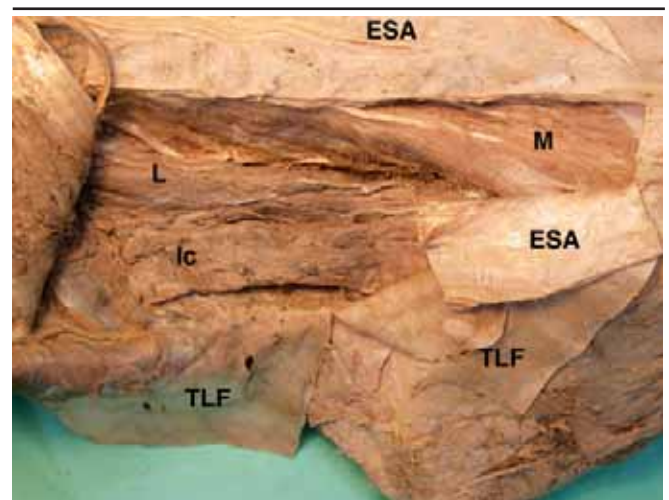
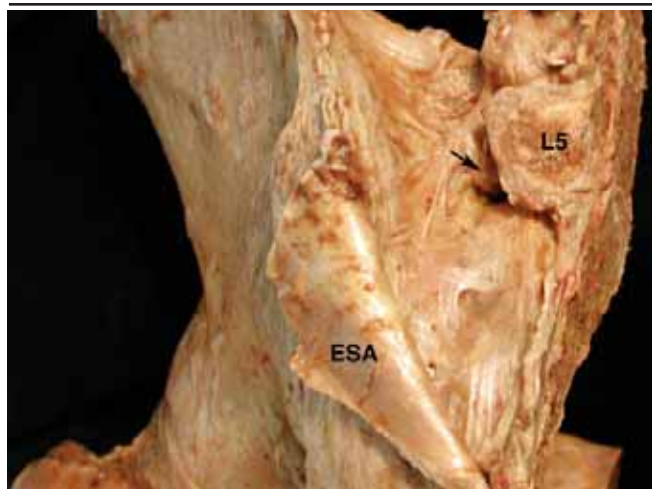

Figure 4. Posterior view of a left half-pelvis. The overlying soft tissues have been removed to reveal the joints and ligaments. The L5/S1 zygapophysial joint (black arrow) is located well below the level of the iliac crest. The L5 spinous process (L5).



CONCLUSIONS

Considering the depth and location of the lumbar zygapophysial joints, and the adjacent and relative anatomy of the lumbar spine (Figure 2), therapists should ask:

1. If I am palpating through all the tissues between the skin and the zygapophysial joint, is the pain that I may be eliciting coming exclusively from this joint?
2. Given that I may or may not be palpating this joint exclusively, how likely am I to be able to detect the amount and quality of movement of this joint when I apply P/A pressure?
3. Considering the depth of the joint, how likely am I to be exclusively palpating the level I report and not another level, or perhaps not a zygapophysial joint at all?

This presentation of anatomy in a manner that is relevant to clinical practice can highlight aspects of assessment and treatment (or perhaps aspects of clinical reasoning) that require careful consideration. This allows researchers and educators to focus their attention on clinically important topics while clinicians benefit from the fresh perspectives that are thus introduced.

Key Point

- Consideration of the zygapophysial joints in situ reveals the difficulties inherent in clinical examination of these structures.

Acknowledgements

The authors gratefully acknowledge Mr Brynley Crosado, Mrs Shannon O'Neill and Mr Russell Barnett for preparation of the anatomical material photographed.

References

- Bogduk N (1997): *Clinical Anatomy of the Lumbar Spine and Sacrum*. Edinburgh: Churchill Livingstone, pp 1-261.
- Bogduk N and Macintosh JE (1984): The applied anatomy of the thoracolumbar fascia. *Spine* 9: 164-170.
- Burns SH and Mierau DR (1997): Chiropractic management of low back pain of mechanical origin. In GF Giles and KP Singer (Eds.): *Clinical Anatomy and Management of Low Back Pain*. Oxford: Butterworth Heinemann, pp 344-357.
- Coppes MH, Marani E, Thomeer RTWM and Groen GJ (1997): Innervation of 'painful' lumbar discs. *Spine* 22: 2342-2350.
- Edmonston SJ, Elvey RL (1997) Physiotherapy management of low back pain of mechanical origin. In GF Giles and KP Singer (Eds.): *Clinical Anatomy and Management of Low Back Pain*. Oxford: Butterworth Heinemann, pp 369-386.
- Giles GF and Singer KP (1997): *Clinical Anatomy and Management of Low Back Pain*. Oxford: Butterworth Heinemann, pp 1-411.
- Grieve GP (1991): *Mobilisation of the Spine*. Edinburgh: Churchill Livingstone, pp 1-426.
- Howarth D, Southee A, Cardew P and Front D (1994): SPECT in Avulsion Injury of the Multifidus and Rotator Muscles of the Lumbar Region. *Clinical Nuclear Medicine* 19: 571-574.
- Kellgren JH (1938): Observations on referred pain arising from muscle. *Clinical Science* 3: 175-190.
- Lewin T, Moffett B and Viidik A (1962): The morphology of the lumbar synovial intervertebral joints. *Acta Morphologica Neerlando-Scandinavia* 4: 299-319.
- Maitland GD (1986): *Vertebral Manipulation*. London: Butterworth Heinemann, Pp 1-390.
- Macintosh JE and Bogduk N (1986): The morphology of the lumbar erector spinae. *Spine* 12: 658-668.
- Macintosh JE, Valencia F, Bogduk N and Munro RR (1986): The morphology of the lumbar multifidus muscles. *Clinical Biomechanics* 1: 196-204.
- McChune T, Clarke R, Walker C and Burton K (1997): Osteopathic management of mechanical low back pain. In GF Giles and KP Singer (Eds.): *Clinical Anatomy and Management of Low Back Pain*. Oxford: Butterworth Heinemann, pp 358-368.
- Mercer SR and Rivett DA (2004): Clinical Anatomy Serving Manual Therapy. *Manual Therapy* 9: 59.
- Yahia L, Rhalmi S, Newman N and Isler M (1992): Sensory Innervation of Human Thoracolumbar Fascia: An Immunohistochemical Study. *Acta Orthopaedica Scandinavica* 63(2): 195-197.

Address for Correspondence

Jon Cornwall. jon.cornwall@clear.net.nz